




# International Journal of Current Trends in Pharmaceutical Research

Journal Home Page: [www.pharmaresearchlibrary.com/ijctpr](http://www.pharmaresearchlibrary.com/ijctpr)



## Research Article

## Open Access

### Hepatoprotective Activity of Ethanolic Extract of Rhizomes of *Curculigo Orchioides*

D. Bargavi\*, Anupam Kanti Bag, Sk. Karimulla, M. Gobinath

Department of Pharmacology, Ratnam Institute of Pharmacy, Pidathapolur, Muthukur, SPSR Nellore, A.P, India.

#### ABSTRACT

Hepatotoxicity in one of the major parameters need to be consider in drug therapy, because most of the drugs in single at low/high doses for a prolonged period or multiple drug therapy causes liver damage. The present study aimed to investigate the possible hepatoprotective activity of ethanolic extract of *curculigo orchioides* (EECO) against paracetamol and ethanol induced hepatotoxicity in albino Wistar rats. Ethanolic extracts of the EECO rizomes were used in the study for determination of hepatoprotective activity against paracetamol and ethanol induced hepatotoxicity in albino Wistar rats. A comparison was also made between the actions of EECO root extracts and a known hepatoprotective drug silymarin. Preliminary phytochemical screening was carried. Biochemical parameters like SGOT, SGPT, ALP and total bilirubin and histopathological studies were used to evaluate the hepatoprotective activity. Acute toxicity studies were carried out according to OECD (420) guidelines and 400 mg/kg BW for both extracts was selected for the present study. Results showed that ethanolic extract in both the models was found to have significant hepatoprotective activity, which reduces the elevated levels of SGOT, SGPT, ALP and Total bilirubin and was almost compared to silymarin. Histopathology showed regeneration of hepatocytes to normal, with the root extracts further confirmed the hepatoprotective activity of extracts of (EECO). Thus results indicate that it is worth undertaking further studies on possible usefulness of the extracts of the roots of (EECO) in hepatotoxicity.

**Keywords:** *Rumex vesicarius*, Paracetamol, Ethanol induced hepatotoxicity in rat

#### ARTICLE INFO

##### CONTENTS

1. Introduction . . . . .	1123
2. Materials and Methods . . . . .	1123
3. Results and discussion . . . . .	1124
4. Conclusion . . . . .	1126
5. References . . . . .	1126

**Article History:** Received 18 August 2015, Accepted 21 September 2015, Available Online 15 November 2015

##### \*Corresponding Author

D. Bargavi  
Department of Pharmacology,  
Ratnam Institute of Pharmacy,  
Muthukur, SPSR Nellore, A.P, India.  
Manuscript ID: IJCTPR2749



PAPER-QR CODE

**Citation:** D. Bargavi, et al. Hepatoprotective Activity of Ethanolic Extract of Rhizomes of *Curculigo Orchioides*. *Int. J. Curmt. Tren. Pharm. Res.*, 2015, 3(6): 1122-1127.

**Copyright** © 2015 D. Bargavi, et al. This is an open-access article distributed under the terms of the Creative Commons Attribution License, which permits unrestricted use, distribution and reproduction in any medium, provided the original work is properly cited.

## 1. Introduction

Liver being an important organ responsible for the metabolism, bile secretion, elimination of many substances, blood detoxifications, synthesizes, and regulation of essential hormones are being affected today by list of severe diseases. The reasons for the liver diseases in the developing countries are hepatitis viruses, environmental toxins parasitic disease and severe drug toxicities. Certain drugs such as antibiotics, chemotherapeutic agents, high doses of paracetamol, carbon tetrachloride (CCL<sub>4</sub>), thioacetamide (TAA) causes hepatotoxicity. Nevertheless, chemical toxins (including acetaminophen, carbon tetrachloride, galactosamine and thioacetamide) are often used as the model substances causing experimental hepatocyte injury in both in vivo and *in-vitro* conditions. Despite the fact that hepatic problems are responsible for a significant number of liver transplantations and deaths recorded worldwide, available pharmacotherapeutic options for liver diseases are very limited and there is a great demand for the development of new effective drugs. [1] Ayurveda proves to be efficacious in such terms. A number of studies have shown that the plant extracts having antioxidant activity protect against CCl<sub>4</sub> hepatotoxicity by inhibiting lipid peroxidation and enhancing antioxidant enzyme activity.

*Curculigo orchioides* (Gaerth) of family Amaryllidaceae, is an herbaceous, tuberous, geophilous, perennial widely distributed all over India. Its rootstock bears several fleshy lateral roots (rhizomes) [2,3,4,5]. It has been reported to be useful in liver ailments [6] & has been shown to possess hepatoprotective activity against carbon- tetrachloride induced liver cell damage in animals. But systematic research on any possible effect of *Curculigo orchioides* on paracetamol and ethanol induced hepatotoxicity seems to be scarce. In the present study, ethanolic extract of the whole plant was screened for hepatoprotective activity in rats using paracetamol and ethanol as hepatotoxin. In this direction to support the herbal recommendation, we designed the present research with the objective of hepatoprotective activity of *Curculigo orchioides* against paracetamol and ethanol induced chronic hepato toxicity.

## 2. Materials and Methods

### Drug and chemicals

All the chemicals were used under analytical grade

### Animals

Male Wister rats weighing 160-200gm were used for the study of anti- inflammatory activity. They were maintained in a well ventilated room with 12:12 hour day/light circle in polypropylene cages and fed with standard pellet diet with water ad libitum. Ethical committee clearance was obtained from IAEC (Institutional Animal Ethics Committee) CPCSEA.

### Plant material

The plant *Curculigo orchioides* (Gaerth) was collected in Tirumala forests, Tirupati, A.P, India in the month of January 2015. The plant sample was further verified and authenticated by a registered botanist Dr. K. Madhava Chetty, Assitant Professor, Department of Botany, Sir International Journal of Current Trends in Pharmaceutical Research

Venkateswara University, Tirupathi, Chittor Dt, AP, India. The voucher specimen of the plant was deposited at the college for further reference.

### Preparation of Extract

The collected rhizome material of *Curculigo orchioides* (Gaerth) was dried in shade for about 15 days, made in to coarse powder in turmeric grinding mill locally. Powdered rhizome was extracted with Ethanol (78C) in soxhlet apparatus for 22 hours. The extract was collected and concentrated under reduced pressure to a semisolid mass. The extract obtained dried in dessicator. The dried extract weighed and the percentage yield was found to be 65% w/w. [7]

### Preliminary phytochemical screening

The *Curculigo orchioides* ethanolic extract was tested for the presence of alkaloids, glycosides (cardiac & anthraquinone), sterols, triterpenoids, flavonoids, tannins, carbohydrates, saponins, phenols, proteins, quinones and amino acids by commonly used precipitation & coloration. [8]. General reactions in the analysis revealed the presence or absence of the compounds in the extract.

**Preparation of the drug for the experimental study:** Extract and the standard drug was administered in the form of suspension (aqueous solution) in water was used for the study.

### Acute Toxicity Studies

Acute oral toxicity studies were performed as per OECD-423 guidelines. Male Wister rats were used for the study. The animals were divided into six groups containing six animals in each group. The extract was administered orally at the doses from 200- 2000 mg/kg. There were no signs of toxicity and mortality was observed up to 2000 mg/kg.[9]

### Paracetamol induced hepatotoxicity

Rats of either sex were divided into 5 groups (n=6) and the duration of the experiment was 9 days.

**Group I:** This group received 0.2% of Carboxy methyl cellulose solution (1ml/kg) once daily for nine days.

**Group II:** This group received Paracetamol (2gm/kg bwt p.o) diluted with sucrose solution 40% W/V in 3 divided doses on day nine.

**Group III:** This group received Silymarin 75mg/kg bwt p.o once daily for nine days + Paracetamol (2gm/kg bwt p.o) diluted with sucrose solution 40%W/V in 3 divided doses on day nine.

**Group IV:** This group received EECO (200mg/kg, bwt p.o) + Paracetamol (2gm/kg bwt p.o) diluted with sucrose solution 40% W/V in 3 divided doses on day nine.

**Group V:** This group received EECO (400mg/kg bwt p.o) + Paracetamol (2gm/kg bwt p.o) diluted with sucrose solution 40%W/V in 3 divided doses on day nine. Paracetamol (2g/kg) was administered orally in a volume of 1 ml/day on fourth day to all the animals except for normal and vehicle control.

### Ethanol induced hepatotoxicity

Rats of either sex were divided into five groups of six animals (n = 6) in each group.

**Group I:** Received 0.2% of Carboxy methyl cellulose solution (1ml/kg) once daily for 21 days, and served as normal control.

**Group II:** Received water (5 ml/kg, p.o.) for 21 days once daily and 40% ethanol (v/v, 2 ml/100 g bwt p.o) for 21 days.

**Group III:**

Received standard drug silymarin (25 mg/kg, p.o.) for 21 days once daily and 40% ethanol (v/v, 2 ml/100 g bwt p.o) for 21 days.

**Groups IV:** Received EECO (200 mg/kg) 21 days once daily and 40% ethanol (v/v, 2 ml/100g body wt p.o) for 21 days.

**Groups V:** Received EECO (400 mg/kg) 21 days once daily and 40% ethanol (v/v, 2 ml/100g body wt p.o) for 21 days.

In both the methods animals were sacrificed 24 h after the last treatment. Blood was collected, allowed to clot and serum was separated at 2500 rpm for 15 min and biochemical investigations were carried out. Liver was dissected out and used for histopathological studies.

**Measurement of biochemical parameters**

Blood sample was collected by retro-orbital puncture and centrifuged at 2000 rpm for 15 min. The serum was separated and used for the estimation of biochemical parameter like ALP, SGOT, SGPT and total bilirubin were assayed.

**Histopathological studies**

Liver pieces preserved in 10% formaldehyde solution were used for histopathological study. The liver tissues were placed in plastic cassettes and immersed in neutral buffered formalin for 24 h. The fixed tissues were processed routinely, embedded in paraffin, cut into 4 mm-thick sections and stained with hematoxylin and eosin (H&E). The extent of paracetamol and ethanol induced hepatic damage was evaluated by assessing the morphological changes in the liver sections.[10]

**Statistical analysis**

The data are expressed as mean  $\pm$  S.E.M. The difference among means has been analyzed by one-way ANOVA. A value of  $p < 0.001$  was considered as statistically significant.

### 3. Results and discussions

Rats treated with Paracetamol developed a significant hepatic damage observed as elevated serum levels of hepato specific enzymes like SGPT, SGOT and Albumin, Total protein and Creatinine when compared to normal control. Pre-treatment with Silymarin, ethanolic extract had showed good protection against paracetamol induced toxicity to liver.

Test indicates a significant reduction in elevated serum enzyme levels with extract treated animals compared to toxic control animals which can be shown in the table no. 1 Rats treated with ethanol developed a significant hepatic damage observed as elevated serum levels of hepato specific enzymes like SGPT, SGOT and Albumin, Total protein and Creatinine when compared to normal control. Pre-treatment with Silymarin, EECO had showed good protection against ethylene glycol induced toxicity to liver. Result indicates a significant reduction in elevated serum enzyme levels with extract treated animals compared to toxic control animals which can be shown in the table no 2.

### Discussion

The liver damage associated with paracetamol overdose is due to the formation of a hepatotoxic metabolite. Therapeutic doses of paracetamol are metabolized mostly to sulphate and glucuronide conjugates. The rest is metabolized to a reactive intermediate which is detoxified by conjugation with glutathione. In overdose, the sulphate and glucuronide conjugation pathways are saturated and more drugs are converted to the reactive metabolite. Liver damage can be prevented by providing glutathione like substances, such as acetylcysteine, so that the reactive metabolite can be removed by conjugation and the liver cells are protected. [11]

In ethanol induced hepatotoxicity, there is increased formation of lipoperoxides, conjugated dienes and malondialdehyde (MDA) and reduced levels of antioxidants like vitamin E and glutathione in the tissues have been demonstrated in experimental animals administered with ethanol as well as alcoholic human subjects.[12] The increased level of AST, ALT, ALP, and bilirubin are conventional indicator of liver injury[13]. Ethanol produces a constellation of dose related deleterious effects in the liver[14]. In chronic alcoholics, hepatomegaly occurs due to accumulation of lipids and proteins in hepatocytes with an impaired protein secretion by hepatocytes. Oxidative stress is one major factor in etiology of ethanol injury, mainly by Kupffer cells through the action of a substance called endotoxin, which is released by certain gram negative bacteria present in the intestine, activates Kupffer cell to generates ROS and pro inflammatory cytokines (TNF alpha, IL 1), both of them can lead to liver damage.

Pretreatment with EECO (200 & 400 mg/kg, p.o) and silymarin (25 mg/kg, p.o) exhibited an ability to counteract the hepatotoxicity by decreasing serum marker enzymes in both the animal models. In case of toxic liver, bilirubin levels are elevated. Hyperbilirubinemia can result from impaired hepatic uptake of unconjugated bilirubin. Such a situation can occur in generalized liver cell injury. Certain drugs (eg., rifampin and probenecid) interfere with the net uptake of bilirubin by the liver cell and may produce a mild unconjugated hyperbilirubinemia.[15]

Bilirubin level rises in diseases of hepatocytes, obstruction to biliary excretion into duodenum, in haemolysis and defects of hepatic uptake and conjugation of bilirubin pigment such as in Gilbert's disease [16]. Liver toxicity decreases the total protein level in serum due to the damage to the tissues. In hepatotoxicant groups, there was a significant increase in total bilirubin and significant reduction in total protein content. Whereas, pre treatment with EECO (200 & 400 mg/kg,p.o) and silymarin (25 mg/kg, p.o) caused significant reduction in total bilirubin and significant increase in total protein. Serum marker enzymes such as SGPT, SGOT, ALP and total bilirubin, showed marked increase and decrease in the level of protein. The same is observed in liver diseases in clinical practice and hence are having diagnostic importance in the assessment of liver function. In the present study, the

extract significantly reduced the elevated levels of above mentioned serum marker enzymes and increase in the levels of protein. Hence, at this point it is concluded that the extracts possess hepatoprotective activity. In support to this study, histopathological results (Fig: A to E) (Fig W to Z) also showed significant activity of the EECO & silymarin. In hepatotoxicant treated animals there will be severe disturbances in the cytoarchitecture of the liver. The same is observed in case of humans who are suffering from major liver disorders. But in EECO (200 & 400 mg/kg, p.o) and silymarin (25mg/kg, p.o) treated group animals exhibited minimal hepatic derangements and intact cytoarchitecture of the liver was maintained. In addition to this there is

regeneration of hepatocytes also observed, which indicating hepatoprotective activity. Finally based on improvement in serum marker enzyme levels and histopathological studies, it is concluded that EECO possesses hepatoprotective activity and thus supports the traditional application of the same under the light of modern science.

#### Anti microbial screening:

The results of antimicrobial studies of newly synthesized compounds reveal that the compounds possess significant antibacterial and anti fungal activities. The results of these studies are given in (Table 7). From Anti bacterial screening results, it has been observed that compounds 11d and 11c possess good activity.

**Table 1:** Effect of ethanolic extract of rhizomes of *Curculigo orchoides* in paracetamol induced hepatotoxicity

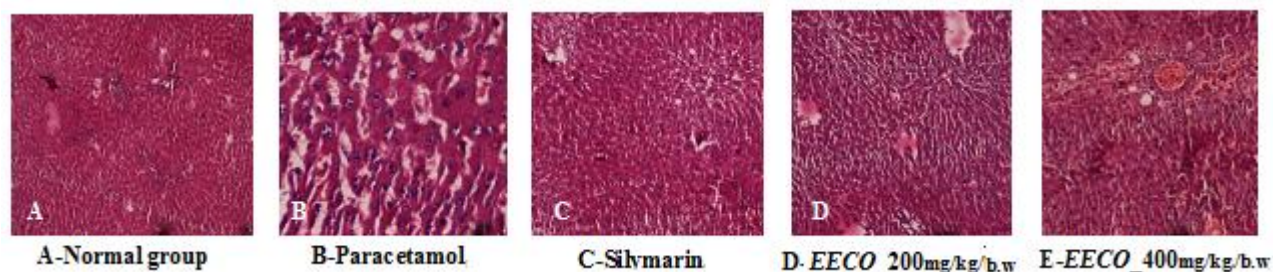
Groups	Treatment Design	SGOT $\mu/l$	SGPT $\mu/l$	Albumin g/dl	Creatinine g/dl	Total Protein mg/dl
1	Normal control	92.23 $\pm$ 2.161	73.0 $\pm$ 1.726	4.083 $\pm$ 0.1044	0.7517 $\pm$ 0.05288	6.883 $\pm$ 0.2315
2	Paracetamol (2gm/kg/b.w)	151.7 $\pm$ 2.165***	105.6 $\pm$ 2.140***	5.567 $\pm$ 0.1764***	1.358 $\pm$ 0.1576***	4.633 $\pm$ 0.1994***
3	Silymarin (25 mg/kg/b.w)	106.3 $\pm$ 2.255***	68.52 $\pm$ 1.545***	4.417 $\pm$ 0.1352**	0.9000 $\pm$ 0.02864***	5.980 $\pm$ 0.1068***
4	EECO (200mg/kg/b.w)	132.0 $\pm$ 3.543**	76.48 $\pm$ 2.543***	4.533 $\pm$ 0.1994**	0.8967 $\pm$ 0.01498**	5.400 $\pm$ 0.1438*
5	EECO (400mg/kg/b.w)	122.3 $\pm$ 6.613***	72.70 $\pm$ 1.548***	4.483 $\pm$ 0.1493***	0.8433 $\pm$ 0.03027**	5.667 $\pm$ 0.1453**

All Values are expressed as mean  $\pm$  SEM, One Way Analysis of Variance, followed by Dunnett's \* P<0.05, \*\* P<0.01 & \*\*\* P<0.001 when compared with paracetamol group

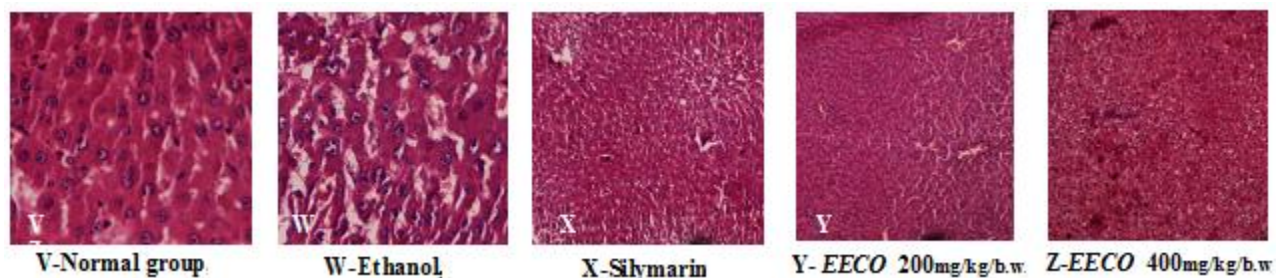
**Table 2:** Effect of ethanolic extract of rhizomes of *Curculigo orchoides* in ethanol induced hepatotoxicity

Groups	Treatment Design	SGOT $\mu/l$	SGPT $\mu/l$	Albumin g/dl	Creatinine g/dl	Total Protein mg/dl
1	Normal control	83.26 $\pm$ 2.201	78.0 $\pm$ 1.726	4.091 $\pm$ 0.128	0.797 $\pm$ 0.0498	6.983 $\pm$ 0.2415
2	Ethanol (2ml/100g/kg/b.w)	149.38 $\pm$ 2.195***	101.6 $\pm$ 2.540***	5.67 $\pm$ 0.1764***	1.324 $\pm$ 0.1476***	4.633 $\pm$ 0.1994***
3	Silymarin (25 mg/kg/b.w)	110.3 $\pm$ 2.255***	80.52 $\pm$ 1.345***	4.211 $\pm$ 0.1256**	0.8900 $\pm$ 0.02764***	6.018 $\pm$ 0.1184***
4	EECO (200mg/kg/b.w)	128.0 $\pm$ 3.415**	90.48 $\pm$ 2.543**	4.433 $\pm$ 0.184**	0.9067 $\pm$ 0.01398*	5.300 $\pm$ 0.1438**
5	EECO (400mg/kg/b.w)	120.3 $\pm$ 4.213***	79.70 $\pm$ 1.548***	4.473 $\pm$ 0.1463***	0.8633 $\pm$ 0.03127**	5.967 $\pm$ 0.453***

All Values are expressed as mean  $\pm$  SEM, One Way Analysis Of Variance, followed by Dunnett's \* P<0.05, \*\* P<0.01 & \*\*\* P<0.001 when compared with G II



**Figure 1: A-E:** Effect of ethanolic extract of rhizomes of *Curculigo orchoides* in paracetamol induced hepatotoxicity



**Figure 2: V-Z:** Effect of ethanolic extract of rhizomes of *Curculigo orchoides* in ethanol induced hepatotoxicity

#### 4. Conclusion

The Hepatoprotective activity was studied in paracetamol and ethanol induced hepatotoxic animal model. The biochemical parameters like serum SGPT, SGOT, albumin, decreases and total protein increases with ethanolic extract of rhizome of *Curculigo orchoides* confirmed the hepatoprotective effect of extract under this study. In liver injury models in rats restoration of hepatic cells with minute fatty changes and absence of necrosis after treatment with extract was observed, indicating hepato protection. Mainly based on the improvement in serum marker enzyme levels it was concluded ethanolic extract of rhizome of *Curculigo orchoides* possesses significant hepatoprotective activity.

#### 5. References

- [1] Akram E, Pejman M, Maryam B, Jalal Z. Hepatoprotective Activity of Cinnamon Ethanolic Extract Against Ccl4-Induced Liver Injury In Rats. EXCLI Journal. **2012**, 11:495-507
- [2] Rajagopalan K, Sivarajan VV, Varier PR. In Warriar PK, Nambiar VPK, Ramankutty C, editors. *Curculigo orchoides* Gaerth. Indian Medicinal Plants. **1994**, 2, 245-8.
- [3] Recknagel RO, Glende EA, Jr. Dolak JA, Walter RL. Mechanism of carbon tetrachloride toxicity. *Pharmacol Ther.* **1989**, 43: 139-54.
- [4] Liver complications. <http://digestive.niddk.nih.gov>
- [5] Liver disease. <http://www.liverfoundation.org>
- [6] Venukumar MR, Latha MS (2002). Hepatoprotective effect of the methanolic extract of *Curculigo orchoides* in carbon tetrachloride-treated male rats. *Indian Journal of Pharmacology*; 34:269-275.
- [7] Khandelwal KR. *Practical Pharmacognosy*, In: Preliminary Phytochemical screening, In: vauation, Nirali Prakashan, Pune, India, **2004**, 149-153 and 157-159.
- [8] Remington JP. Remington: The science and practice of pharmacy, 21st edition, Lippincott Williams & Wilkins, 773-774.
- [9] OECD, 2002. Acute oral toxicity. Acute oral toxic class method guideline 423 adopted 23.03.1996. In: Eleventh Addendum Bangladesh J Pharmacol 2013; 8: 263-268 267 to the, OECD, guidelines for the testing of chemicals organisation for economics co-operation, development, Paris, June, **2000**, p 11.
- [10] Chandrasekaran, S.K., Benson, H., Urquhart, J., 1978. Methods to achieve controlled drug delivery: the biochemical engineering approach. In: Robinson, J.R. (Ed.), Sustained and Controlled Drug Delivery Systems. Marcel Dekker, New York, p 557–593.
- [11] Grahamesmith DG and Azonson JK. (1984). The drug therapy of gastro intestinal, hepatic and biliary disorders Chapter 23 In: Oxford Textbook of *Clinical Pharmacology and Drug Therapy*, Oxford University Press, Oxford, (1): pp. 383-385.
- [12] Boots AW, Haenen GR and Bast A. Health effects of quercetin: from antioxidant to nutraceutical. *Eur J Pharmacol*, **2008**, 585: 325-337.
- [13] Festa F, Aglitti T, Duranti G, Ricordy R, Peticone P and Cozzi R. Strong antioxidant activity of ellagic acid in mammalian cells in vitro revealed by the comet assay. *Anticancer Res*, **2001**, 21: 3903-3908.
- [14] Boyle SP, Dobson VL, Duthie SJ, Hinselwood DC, Kyle JA and Collins AR. Bioavailability and efficiency of rutin as an antioxidant: a human supplementation study. *Eur J Clin Nutr*, **2000**, 54: 774-782.

- [15] Kukongviriyapan V, Janyacharoen T, Laupattarakasaem P, Kanokmedhakul S and Chantaranonthai P. Hepatoprotective and antioxidant activities of *Tetracera loureiri*. *Phytother Res*, **2003**, 17: 717-721.
- [16] Govindarajan R, Vijayakumar M, Rao CV, Shirwaikar A, Mehrotra S and Pushpangadan P. Healing potential of *Anogeissus latifolia* for dermal wounds in rats. *Acta Pharm*, **2004**, 54: 331-338.