



Histopathological effect of the pesticide Lindane in the Gill tissue of the freshwater fish, *Cyprinus carpio*.

S.Binukumari* and Vasanthi.J

PG and Research Department of Zoology, Kongunadu Arts and Science College, Coimbatore, TamilNadu

NCBC'14, 27 August 2014, Organized by PG & Research Department of Biotechnology,
Sree Narayana Guru College, K.G. Chavadi, Coimbatore, India-641105.

Contents

1. Introduction	165
2. Experimental	166
3. Results and discussion	166
4. References	167

*Corresponding author

S. Binukumari

PG and Research Department of Zoology,
Kongunadu Arts and Science College,
Coimbatore, TamilNadu, India

Manuscript ID: NCBC2014-JPBR2273



PAPER QR-CODE

Copyright @ 2014, JPBR

All Rights Reserved

Abstract

A thorough knowledge of normal histology is essential for the understanding of the altered structure seen in the various conditions of disease. The off target movement of chemicals used in industry and agriculture are usually unavoidable, these chemicals get into natural water and may cause significant tissue damage in fish. Generally industrial wastes includes a wide variety of chemicals all of these chemicals of industrial waste are toxic to animals and may cause death or sub lethal pathology of liver, kidneys, reproductive system, respiratory system or nervous system in both invertebrate and vertebrate aquatic animals. Histology acts as an integrated parameter, providing a more complete evaluation of the organisms' health, effectively monitoring the effects of exposure to environmental pollutants. The median lethal concentration (LC₅₀) of Lindane to fish *Cyprinus carpio* for 96 h was found to be 0.32 ppm. In sublethal concentration (1/10th of LC₅₀ 96h value, 0.032 ppm) fishes were exposed for 10 days, 20 days and 30 days. Histopathological lesions were noted in the gill tissue when compared to the control.

Keywords: Histopathology, Pesticide, lethal concentration, gill

1. Introduction

The advantage of histopathology as a biomarker lies in its intermediate location with regard to the level of biological organization. Histological changes appear as a medium-term response to sub-lethal stressors, and Histology provides a rapid method to detect the effects of irritants, especially chronic ones, in various tissues and organs. The exposure of fish to chemical contaminants is likely to induce a number of lesions in different organs. Gills are suitable organ for histological examination in order to determine the effect of pollution. Jiraungkoorskul *et al*, (2002) reported histopathological changes in the liver and gills of Nile tilapia, *Oreochromis niloticus*, exposed to glyphosate herbicide.

2. Materials and Methods

They were collected from the Aliyar fish farm, pollachi stocked and acclimatized for a time period of 10-15 days in the laboratory conditions in glass aquaria containing dechlorinated water. The water of the aquarium was aerated continuously through stone diffusers connected to a mechanical air compressor. Water temperature ranged between $26\pm 5^{\circ}\text{C}$ and the pH was maintained between 6.6 and 8.5. Fish were fed twice daily alternately with rice bran and oil cakes. For the present study, matured adult fishes were exposed to different concentrations viz LC_{50} of Lindane for 10, 20 and 30 days continuously. Three replicates of ten fishes for each concentration of the pesticides were used. In these aquaria water was replaced daily with fresh treatment of pesticides. Each experiment was accompanied by its respective control.

Three groups of fishes were exposed to $(1/10^{\text{th}})$ of the pesticide 'Lindane' for 10 days, 20 days and 30 days. Another group was maintained as control. All the groups received the same type of food and other conditions were maintained similarly. At the end of exposure period, fish were randomly selected for histopathological examination. Tissues of gills, were isolated from control and experimental fish. Physiological saline solution (0.85% NaCl) was used to rinse and clean the tissues. They were fixed in aqueous Bouin's solution for 48 hrs, processed through graded series of alcohols cleared in xylene and embedded in paraffin wax. Gills alone were processed by double embedding technique. Sections were cut at 6μ thickness stained with Haematoxylin Eosin, dissolved in 70% alcohol (Humason, 1962) and were mounted in Canada Balsam. The photographs at 200x magnification were taken with computer aided microscope (Intel play Qx3, Intel Corporation, Made in China).

3. Results and Discussion

Unexposed fish gill histology revealed the presence of primary and secondary gill lamellae, pillar cell, inter lamellar region and central axis (ph.m.1). The fish exposed to Lindane for 10 days exposure period, exhibited marked histopathological changes, such as curling of secondary lamellae (ph.m.2.) After 20 days exposure, degenerated secondary lamellae were noted. (ph.m.3.) The severity of the damage become more noticeable after 30 days of exposure leading to collapsed secondary lamellae (ph.m.4). According to Eller (1971a) the epithelial layer of secondary lamellae of gill of fish forms a barrier between the fish blood and surrounding water. Gaseous exchange needed to sustain life which takes place through this barrier and any thickening induced by physical, chemical or biological agents hinders the respiratory function of this organ. Erkmen *et al.* (2000) studied the histopathological effects of Cyphenothrin on the gills of *Lebistes reticulates*. The results showed necrosis, degeneration of secondary lamellae due to odema, shortening of secondary lamella.

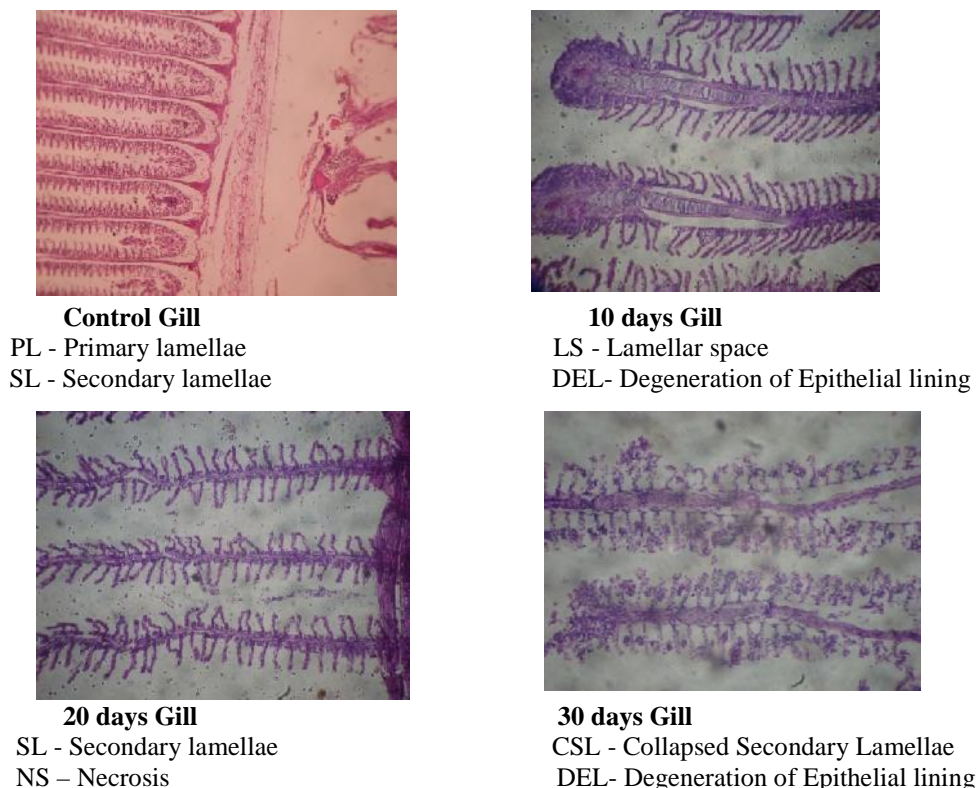


Figure 1: Histopathology of Gill Tissue

4. References

1. Jiraungkoorsul, W., Upatham E.S., Kruatrachue M., Sahaphong S., Vichasri-Grams S., Pokethitiyook P. Histopathological effects of round up, a glyphosate herbicide, on Nile tilapia (*Oreochromis niloticus*), Science Asia, **2002**, 28, pp 121-127.
2. Humason, G.L. (1962). Animal tissue technique III (ED) W.H. Freeman and Co., San Fransisco.
3. Eller L.L. Gill lesions in freshwater teleosts. In: The Pathology of fishes. Eds: Riubelin W E, Migaki G Univer.Wis.Press, **1971a**, pp.305-330.
4. Erkmén, B., Caliskan, M. and Yeril, S.V. Histopathological effects cyphenothrin gills of the *Lepistes reticulatus*. *Vet.Hum. Toxicol.* **2000**, 42:5-7.