Available online at www.pharmaresearchlibrary.com/ijmpr

ISSN: 2321-2624
Review Article

International Journal of Medicine and Pharmaceutical Research
www.pharmaresearchlibrary.com/ijmpr
IJMPR, 2013: Vol.1(4): 367-375

Horizontal Root Fracture: Diagnosis, Prevention and Management-A Review

Mithra N Hegde*, Ravi Dahiya, Shishir shetty
Department of Conservative Dentistry and Endodontics
A.B. Shetty Memorial Institute of Dental Sciences, Nitte University, Mangalore
*E-mail: drhegdedentist@gmail.com
Available online 5 October 2013

Abstract
Traumatic injuries constitute a true dental emergency and the patients experiencing trauma, are not only physically, but also psychologically affected. Tooth fractures are commonly encountered dental emergencies with root fracture being one of the unusual sequelae. It is well recognized that preventive measures such as tooth and face protection can significantly reduce the severity of injuries with more emphasis placed on educating youngsters and teenagers on how to avoid traumatic injuries to their teeth. Horizontal root fractures are the fractures involving dentin, cementum and pulp as a result of trauma to teeth and periodontium which occurs mainly due to falls or sports activities. Horizontal root fracture cases are clinically challenging and need to be properly diagnosed with prompt treatment planning and evidence based multidisciplinary approach for management. This review article elaborates the diagnosis, prevention, treatment planning and subsequent healing patterns along with the factors influencing the prognosis of the affected tooth.
Key words: Trauma, Root Fracture, Emergency, Injury

Introduction

The oral region comprises 1% of the total body area, yet it accounts for 5% of all bodily injuries. The incidence of traumatic dental injuries is 1%–3%, and the prevalence is 20%–30%.(1) Tooth fractures are commonly encountered dental emergencies with root fracture being one of the unusual sequelae. Root fractures are the fractures involving the dentine, cementum and pulp. They are broadly classified as horizontal and vertical root fractures. There is a wide variety of presentations as to the location, angulations, and severity of these fractures, which provides diagnostic as well as treatment plan challenges. Of particular interest to clinicians (and clinically challenging) are the cases of root fractures as their management may involve an interdisciplinary/multidisciplinary treatment approach (2). The majority of fractures and displacements result from simple accidents and involve little or more than local oral tissues. Every effort should be made to restore them skilfully to their original appearance and functioning without producing additional trauma or endangering the integrity of the teeth.

Etiology

The most common reasons for root fractures in the permanent dentition is physical trauma caused during falls, automobile accidents, fights or sporting events. Any object striking the teeth may also lead to a similar injury. The overall incidence of horizontal root fracture is low and has been reported to range from 0.5%–7%. (2) The most common cause is falls comprising between 26% and 82% of all sustained injuries depending on the subpopulation investigated.(3) Sports-related injuries are generally the second most common cause.(4) Predisposing factors include, children of age 1-2 years (when they learn to walk) and teenagers (when they get more involved in sports activities).(5) In primary dentition uncomplicated crown fractures tend to be the most common type of dental injury due to more resilient and elastic supporting structure in primary dentition which makes primary teeth more prone to displacement rather than fracture (5), lack of mouthguard during sports activities (6), maxillary incisors because of their prominent location in the dental arch and lack of natural protection.(7) In addition, root fractures may occasionally be caused by parafunctional habits, traumatic occlusion and iatrogenic causes like cervical weakening during biomechanical preparation (8), long term intracanal calcium hydroxide dressing (9).

Classification

Horizontal/transverse root fractures are most commonly seen in young adults due to direct physical trauma in the anterior region. They can be further sub-classified on the basis of:

- Location of fracture line: cervical, middle and apical;
- Extent of fracture: partial and total;
- Number of fracture lines: simple, multiple and comminuted;
- Position of coronal fragment: displaced and not displaced. (10)

Diagnosis

Patients with dental injuries should be examined as soon after the traumatic incident as possible. The examination process of trauma patients should include the possibility of concomitant injury to adjacent tissues and the frequent need to provide insurance and/or a legal report, or referral in case of medical emergency.

History

A brief history of the traumatic event should be recorded involving:

- Time and place of event;
- Reason for the injury (eg. fights or sports);
- Previous dental injuries;
- Spontaneous pain or sensitivity; and
- Other associated symptoms following injury (unconsciousness, drowsiness, vomiting or headache).

IADT (Internationl Association of Dental Traumatology) guidelines (11,12,13,14)

Diagnostic Signs Table.1

Visual signs	The coronal segment may be mobile and in some cases displaced. Transient crown discoloration (red or grey) may occur. Bleeding from the gingival sulcus may be noted.
Percussion test	The tooth may be tender.
Mobility test	The coronal segment may be mobile.
Sensibility pulp test	Sensibility testing may give negative results initially, indicating transient or permanent neural damage. Monitoring the status of the pulp is recommended.
Radiographic findings	The root fracture line is usually visible. The fracture involves the root of the tooth and is in a horizontal or diagonal plane.
Radiographs recommended	Periapical, occlusal and eccentric exposures.

Pulp vitality test

Tooth's vascular supply can be evaluated by using laser Doppler flowmetry (LDF) (15) or pulse oximetry (16). LDF assessment for human teeth should be performed at 4 weeks following the initial trauma, and repeated at regular intervals up until 3 months. Pulse oximeter is another promising tool for vitality testing found to be better than the cold test and electric pulp test. Most recent trauma guidelines suggest that in addition to conventional radiography, CBCT scans may be considered for the diagnosis of HRF. However, concerns have been raised because of higher levels of radiation, higher cost to the patient, and the need for sufficient training to properly evaluate the entire data set.(2)

Differential diagnosis

Similar clinical presentation and common etiological factors makes alveolar fracture the most important differential diagnosis of intra alveolar root fractures. Based on IADT Guidelines, alveolar fracture can be diagnosed on the following basis (11,12,13,14) :

Table.2

Description	A fracture of the alveolar process; may or may not involve the alveolar socket. Teeth associated with alveolar fractures are characterized by mobility of the alveolar process. Several teeth typically will move as a unit when mobility is checked. Occlusal interference is often present.
Visual signs	Displacement of an alveolar segment. An occlusal change due to misalignment of the fractured alveolar segment is often noted.
Percussion test	Tender.
Mobility test	Entire segment mobile and moves as a unit.
Sensibility pulp test	Usually negative.

Radiographic findings	The vertical line of the fracture may run along the PDL or in the septum. The horizontal line may be located at any level, from the marginal bone to the basal bone.
Radiographs recommended	Occlusal, periapicaland eccentric exposure. A panoramic or a cone beam exposure may be useful.

Prevention

Appropriate management includes primary prevention, i.e. avoidance of pathology development, and secondary prevention, i.e. early diagnosing and treatment of the pathology before significant morbidity occurs (17).

Primary prevention

Healthcare providers, such as dentists, dental hygienists, physicians, and nurses, have a significant role in primary prevention of dental trauma which includes providing of knowledge and motivation to patients and communities, promotion of preventive measures such as mouth guard and face masks and treatment of dental caries and faulty restorations as well as malocclusions.

Mouthguards

3 basic types (on the basis of how they are manufactured and used) (18):

1. Stock prefabricated
2. Mouth-formed
3. Custom-made

The ability of a mouthguard to protect against frequent injuries, often caused by a direct blow to the teeth, is believed to depend on the following three factors:

(i) Its ability to absorb and dissipate the force of impact
(ii) Its ability to provide reinforcement at the lingual surface of the maxillary incisors; and
(iii) Its ability to gain support from the mandibular dentition reinforcing the maxillary dentition and alveolar bone.

Clinicians have to notice the discrepancy between awareness, knowledge, and ‘compliance’. When recommending mouthguard, dentists should prefer custom-made mouthguards, which offer superior protection than a prefabricated design.

Secondary prevention

The prompt on-site management of dental trauma, especially in cases of avulsion, by dental professionals, emergency physicians, medics, paramedics, teachers, coaches, and laypersons is essential for a favorable long-term prognosis.

Based on the IADT guidelines, following steps are recommended for dental professionals:

1. Publication of communicative articles regarding prevention and management of dental trauma
2. Providing lectures about prevention and management of dental trauma in front of school staff and parents, healthcare personnel etc.
3. Recognize the high risk.
4. During examination, look for intraoral signs of potentially damaging habits of the patient (bruxism, foreign bodies).
5. Educate your patients against lip and intraoral piercing/ornaments.
6. Offer mouthguards to professional sportsmen and teams as well as semi professional (e.g. high school teams) and amateur sportsmen.
7. Distribute hand-outs regarding prevention and first aid of dental trauma.

Management of root fracture

Most guidelines for the management of trauma do not give a minimum data set that should be recorded at the first visit for different types of dento-alveolar injuries. It is very essential to establish the prognostic factors at the time of diagnosis or initial treatment that affect pulp and periodontal healing and tooth survival. Following factors should be considered:

1. If concomitant crown fracture or concomitant periodontal injury is present.
2. Degree of displacement of coronal fragment (in mm).
3. Interference with the occlusion.
4. Apical maturity.
5. Location of fracture.
6. Displacement of coronal fragment on radiograph at the fracture site.
7. Positive response to pulpal sensibility tests at the time of injury.

Management of root fractures can be divided into treatment of apical-, middle- and cervical-third fractures.

Apical-third fracture

In 1958, *Lindahl* et al. observed that root fractures could heal even after endodontic treatment of the tooth. According to *Cvek et al*., in most of the teeth, pulp necrosis was confined to the coronal fragment, which is accordance with the histological findings by *Andreasen and Hjorting-Hansen*. (20)

Basically, five types of conservative endodontic treatment have been described (21) :

1. Cleansing and gutta-percha (GP) filling of the root canal of the coronal fragment only;
2. Cleansing and filling of the root canal in both fragments;
3. Cleansing and GP filling of the root canal of the coronal fragment and surgical removal of the apical fragment;
4. Treatment of the root canal with calcium hydroxide followed by filling with GP; and
5. Partial pulpotomy of exposed vital pulps of root-fractured teeth.

Middle-third fracture

According to IADT guidelines (11):

- Rinse exposed root surface with saline before repositioning.
- Reposition, if displaced, the coronal segment of the tooth as soon as possible.
  It can be done by simple digital manipulation (finger pressure), or an orthodontic intervention may be required for proper alignment.
- Check position radiographically.
- Stabilize the tooth with a flexible splint for 4 weeks.
- If the root fracture is near the cervical area of the tooth, stabilization is beneficial for a longer period of time (up to 4 months).
- It is advisable to monitor healing for at least 1 year to determine pulpal status.
- If pulp necrosis develops, root canal treatment of the coronal tooth segment to the fracture line is indicated to preserve the tooth.

Types of splints used are:

Orthodontic band-arch wire splint, Cap splint, Proximal bonding with composite, Bonded orthodontic wire, TTS (*Titanium Trauma Splint)* , Fiber splint etc.

Patient instructions following splinting include soft food for 1 week and maintainance of good oral hygiene (brushing with a soft brush and rinsing with chlorhexidine 0.1 %).

Cervical-third fracture

An intra-alveolar fracture in the cervical part of the root is a rare injury; reported frequencies vary between 6% and 19% of intra-alveolar root fractures. Treatment options are decided upon by the position of the fracture line, length of the remaining root segment and the presence or absence of a coronal segment. The prognosis is considered to be poor due to a short mobile coronal fragment, with less probability of healing with hard tissue, and possible bacterial contamination of necrotic pulp tissue from the gingival crevice.

Re-attachment

In cases where fracture occurs at or coronal to the level of alveolar bone crest, reattachment of the fractured segments can be attempted. This is done with the help of light transmitting or fibre-reinforced posts and resin-based composite material. (22)

Permanent fixation

Splinting for cervical-third root fracture should be carried out for a period of 4 months. In patients with optimal oral hygiene, permanent fixation of the coronal fragment to adjacent teeth at the proximal contact areas with a resin-based composite or reattachment of fractured segments can also be tried.

Post and core

Post and core followed by crown are indicated in cases where the coronal segment is lost, the fracture line is above the alveolar bone crest and the apical root segment has sufficient length. In cases where exposure of crown margins is required, a simple gingivoplasty, gingivectomy or an apical positioned flap surgery is performed (23).

Orthodontic extrusion

Also known as forced eruption or orthodontic eruption carried out in cases where the fracture line extends deeply in the interproximal or labial surface and when crown lengthening would be unaesthetic. This involves application of traction forces to the tooth, causing vertical extrusion of the root and marginal apposition of crestal bone (figure 1). The gingiva, epithelial attachment, and newly formed crestal bone are also extruded, along with the tooth, leading to

a coronal shift of the marginal gingiva. Thus there is no loss of any bone or periodontal support. The techniques used for orthodontic extrusion include the use of removable or fixed orthodontic appliance (24).

Figure.1

Intra-alveolar transplantation of the fractured tooth

It is carried out for patients who are treated on an emergency basis, having severe luxation of the fractured root. In this technique, the tooth is carefully extruded to the required position by marginal luxation and stabilized by interdental suturing and surgical dressing. If the fracture line is more apical on the labial side, a rotation of 180° is given before fixation. With this method the bone support around the root is usually lost (25).

Extraction

The time and cost of potential restoration of a horizontally fractured tooth must be weighed against the alternatives of implant, fixed or removable prosthesis. In cases where conservative treatment is not possible, the fractured tooth should be extracted without causing any damage to the alveolar processes.

Follow up

- Splint removal and clinical and radiographic control after 4 weeks in apical third and mid-root fractures. However, if the root fracture is near the cervical area the splint should be kept on for up to 4 months.
- Clinical and radiographic control after 6-8 weeks.
- Clinical and radiographic control after 4 months. If the root fracture is near the cervical area the splint should be removed at this session.
- Clinical and radiographic control after 6 months, 1 year and yearly for 5 years.
- Follow-up may include endodontic treatment of the coronal fragment if pulp necrosis develops. The decision for endodontic treatment may be taken after three months of follow-up if the tooth still does not respond to electrometric or thermal pulp testing and if radiographs show a radiolucency next to the fracture line.

Healing

Clinically and radiographically the type of fracture healing is classified according to criteria listed by *Andreasen & Hjørting-Hansen* (26).

The pulp injury may vary according to the extent of trauma from almost none to stretching or rupture at fracture level. Repositioning in the latter case supposedly facilitates pulp revascularization in the coronal part of the pulp. The PDL injury may, as with the pulp injury, range from probably none to stretching and rupture. As with the pulp, no studies exist as to the effect of repositioning on PDL healing in fractured teeth. The final tissues to heal, dentin and cementum, depend upon the activity of odontoblasts and cementoblasts. There does not appear to be any information on the effect of repositioning and splinting upon these two cell activities.

1. Healing with interposition (fusion) of hard tissue: healing with hard tissue, fragments are in close contact and the fracture line is not visible or indistinctly outlined.(Figure 2)
2. Healing with interposition of only PDL tissue: fragments are close but separated by a distinct radiolucent line and there is rounding-off of fracture edges next the PDL. (Figure 3)
3. Healing with interposition of bone and PDL between the fragments: fragments are separated by ingrowth of bone surrounded by a periodontal-like space. (Figure 4)
4. No healing: persistent or widened space between the fragments and presence of a radiolucency in the alveolar bone adjacent to the root fracture.(Figure 5)

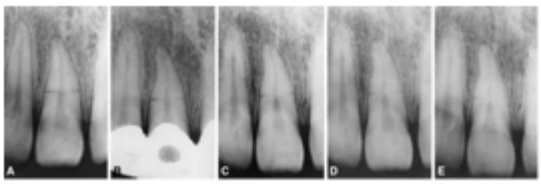

Fig.2 Healing with hard tissue formation

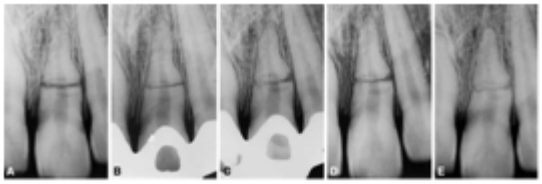

Fig.3 Healing with interposition of PDL

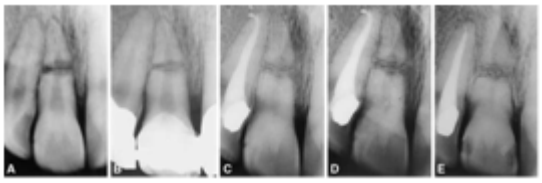

Fig.4 Healing with interposition of bone and PDL.

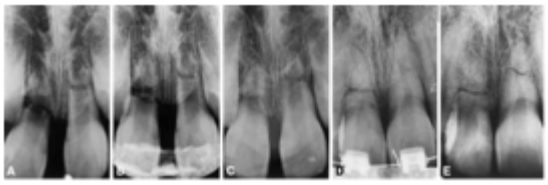

Fig.5 No healing

Pulp and periodontal tissue repair - after dental trauma

The healing after traumatic dental injuries has long been known to be very complex and often unpredictable. The type of healing is determined upon the stem cell capacity in the given location. Furthermore, a race between different tissue compartment cells whereby a damaged PDL area can be occupied by bone cells and a pulp space may become invades by PDL cells, PDL, and bone cells or bone cells alone. These facts complicate significantly the healing after trauma and surgery (27).

Pulp loss

If pulp is lost in teeth with immature root formation, pulp revitalization may occur, although at a slower rate compared with a situation where the ischemic pulp is preserved.

Pulp ischemia

This event happens in all tooth displacement injuries where the vascular supply is damaged or ruptured. Such events may lead to pulp regeneration, pulp repair with accelerated dentin formation (Pulp Canal Obliteration), or pulp metaplasia where PDL ± bone invade the pulp and finally a sterile or infected pulp necrosis may occur. The revitalization process appears to be very dependent upon the size of the apical foramen, being very frequent with apical diameters above 1.0 mm and infrequent with diameters below 0.3 mm.

Periodontal ligament

Periodontal ligament facing the alveolar bone if lost may regenerate completly. In situations of periodontal ligament ischemia or contusion, may lead to repair-related resorption or resorption ankylosis. Whereas if periodontal ligament facing the cementum is lost may lead to ankylosis. Cementum loss may occur in the cases of root fractures. New cementum will be formed on the exposed dentin starting from existing cementoblasts next to the tissue loss.

Effect of pre-injury and injury factors

Factors such as sex, age, stage of root development, fracture type, location of fracture and severity of dislocation affects healing and repair (28).

Root development

Immature teeth having widely patent apices and at the same time short pulp length that can facilitate pulpal revascularization. In root-fractured teeth with not more than one-half completed root formation, hard tissue healing is the predominant healing type.

Age

Healing with interposition of bone and PDL occurred in the period from 9 to 15 years of age, a phenomenon, which must be related to the vertical growth of the alveolar process, which may invite interposition of both PDL and bone.

Fracture location

A surprising factor is that cervical fractures has slightly better chance of healing than fractures located at the middle or apical one-third of the root. This might be explained by the shorter distance needed to be revascularized in the cervical region. This finding seems to support the treatment guideline that cervical root fractures have a fair chance of healing and preservation should be attempted.

Dislocation

Hard tissue healing is significantly more prominent in the non-displaced teeth.

Mobility

Mobility of the coronal fragment has a negative influence upon healing due increased mobility, apart from disruption of the PDL, also represent a risk that the pulp has been ruptured at the fracture line.

Sensibility

The nerve supply to the pulp can function even with some displacement of the coronal fragment. This must imply that the pulp can be stretched to certain limits. With greater separation, the likelihood of the development of pulp necrosis increases.

Effect of treatment factors

Repositioning

Optimal repositioning favours pulp healing instead of healing processes from the PDL. This could be due to reduction of the risk of invasion of bacteria through a minimal coagulum in well repositioned cases, as a coagulum is a good substrate for bacterial growth. (29)

Splinting and splinting period

An absolute immobility by splinting procedure may lead to disturbance of natural healing events due to its restriction of mobility between the injured surfaces. This immobilization may result in reduced circulation. Fiber splint has been found to be slightly flexible and application implies minimal handling of the injured tooth and should be preferred. Splinting and no splinting do not relate to healing in non-displaced teeth. With respect to displaced teeth, positive effect of no splinting of root fractured teeth should be interpreted with caution. Splinting beyond 3–4 weeks is not necessary for root fractures in general. An exception could be fractures located in the cervical region,which usually are very mobile and might, therefore, require a longer splinting period (2–3 months) to permit significant callus formation. (29)

Treatment delay

The lack of a beneficial effect of early treatment after trauma is surprising. Further studies are needed to investigate the effect of treatment delay upon pulp and periodontal healing, not only following root fractures, but also for other groups of dental injury. (29)

Antibiotics

The slightly negative (but not significant) role of antibiotics upon pulp necrosis and hard tissue healing needs an explanation. The obvious consideration is that antibiotics are only administered in cases with severe injury. (29)

Tooth mobility changes subsequent to root Fractures

Various instruments have been used to measure tooth mobility changes subsequent to root fractures. The mobility can be tested using Muhlemann's testing instrument and Periotest (Medizintechnik Gulden e. K., Modautal, Germany).When healing take place, abnormal mobility is reduced according to the type of healing. Healing with interposition of hard tissue (HT) results in normal mobility, whereas healing with interposition of periodontal ligament (PDL) in the fracture line results in increased mobility. Finally, non-healing owing to an infection in the coronal pulp has been found to be related to excessive loosening because of the breakdown of the lateral periodontium. (30)

Sequelae

Not only can intralveolar root fractures have different types of healing, they can also have various types of sequelae, such as:

Pulp survival with canal obliteration

One of the most frequent findings in an intraalveolar root fracture is pulp canal space calcification, also known as calcific metamorphosis, which is typically associated with vital pulp tissue, even though the canal space may not be visible radiographically. Therefore, endodontic treatment is not indicated.

Internal resorption

Internal resorption is the pathological reaction of the dental pulp as a consequence of a long standing chronic pulp inflammation. Intrpulpal infection has been associated with this resorption, and thought to be a factor in its stimulation. The resorption may be transient, when lacunae are present within the canal walls, or the resorption may become progressive when odontoblasts are destroyed, not permitting predentin to be laid down.

External resorption

Over time follow up radiographs may reveal a resorptive process developing around the areas of the root that are proximal to the fracture site. This is typically a transient, self-limiting process. Replacement resorption (i.e. ankylosis) can sometimes be seen in areas surrounding the apical fragment of teeth with intraalveolar root fractures in the apical third.

Loss of crestal bone

Loss of crestal bone is one of the most complicated sequelae of intraalveolar root fractures, especially occurring when there is a coronal root fracture that extends to the gingival sulcus, exposing the fracture site directly to the oral cavity. This generally results in a poor prognosis for the coronal fragment.

Conclusion

Despite of continuous efforts in reducing the cases of dental traumas, incidence of dental trauma remains unchanged and is at a relatively high level for children and young adults. The expanded IADT guidelines are useful, and when followed, they can lead to better outcomes than when no guidelines are used. Thorough knowledge of etiological factors, diagnostic methods, differential diagnosis, and factors determining the prognosis, are critical to design a suitable treatment protocol which may involve an interdisciplinary/multidisciplinary treatment approach to manage horizontal root fracture cases more predictably. Adequate treatment in the dental office, as well as the proper long term and regular follow up are imperative for a successful outcome of such incidents.

References

1. Lars Andersson. Epidemiology of Traumatic Dental Injuries. JOE — Volume 39, Number 3S, March 2013.
2. Orhan K, Orhan AI, Tulga F. Management of untreated traumatized permanent incisors with crown and root fractures: a case report. *Quintessence Int* 2009; 40:647–654.

3. Zuhal K, Semra OE, Huseyin K. Traumatic injuries of the permanent incisors in children in southern turkey: a retrospective study. Dent Traumatol 21:20-25, 2005.
4. Cornwell H: dental trauma due to sports in pediatric patients. J calif Dent Assoc 33: 457-461, 2005.
5. Rocha MJ, Cardoso M: Traumatized permanent teeth in Brazilian children assisted at the Federal University of Santa Catarina,Brazil, Dent. Traumatol 17:245-249, 2001.
6. Elisa B. Bastone, Terry J. Freer, John R. McNamara. Epidemiology of dental trauma: a review of the literature. Australian Dental Journal 2000; 45:(1):2-9.
7. Zuhal k, Semra OE Huseyin K: Traumatic injuries of permanent incisors in children in southern turkey: a retrospective study, Dent Traumatol 21: 20-25, 2005.
8. Caroline Zamin, Yara Terezinha Correa Silva-Sousa, Aline Evangelista Souza-Gabriel, Danielle Furtado Messias, Manoel Damia˜o Sousa-Neto. Fracture susceptibility of endodontically treated teeth. Dental Traumatology 2012; 28: 282–286.
9. Glen E. Doyon, DMD, Thom Dumsha, MS, DDS, MS, and J. Anthony von Fraunhofer, MSc, PhD† .Human Root Dentin Exposed to Intracanal Calcium hydroxide. JOE - 2005; 31(12): 895-897.
10. Neeraj malhotra, M Kundabala. A review of root fractures. Dent Update 2011; 38:615–628.
11. DiAngelis AJ, Andreasen JO, Ebeleseder KA, et al. International Association of Dental Traumatology guidelines for the management of traumatic dental injuries: 1—fractures and luxations of permanent teeth. Dent Traumatol 2012;28:2–12.
12. Andersson L, Andreasen JO, Day P, et al. International Association of Dental Traumatology guidelines for the management of traumatic dental injuries: 2—avulsion of permanent teeth. Dent Traumatol 2012;28:88–96.
13. Malmgren B, Andreasen JO, Flores MT, et al. International Association of Dental Traumatology guidelines for the management of traumatic dental injuries: 3—injuries in the primary dentition. Dent Traumatol 2012;28: 174–82.
14. Online (www.iadt-dentaltrauma.org).
15. Ebihara A, Tokita Y, Izawa T, Suda H. Pulpal blood flow assessed by laser Doppler flowmetry in a tooth with a horizontal root fracture. Oral Surg Oral Med Oral Pathol Oral Radiol Endod. 1996 Feb;81(2):229-33.
16. Velayutham Gopikrishna, Kush Tinagupta, and Deivanayagam Kandaswamy. Comparison of Electrical, Thermal, and Pulse Oximetry. Methods for Assessing Pulp Vitality in Recently Traumatized Teeth. J Endod 2007;33:531–535.
17. Liran Levin, Yehuda Zadik. Education on and prevention of dental trauma: it’s time to act! Dental Traumatology 2012; 28: 49–54.
18. Asgeir Sigurdsson, Cert endo. Evidence-based Review of Prevention of Dental Injuries. J Endod 2013;39:S88–S93.
19. Lindahl B. Transverse intra-alveolar root fractures. Roentgen diagnosis and prognosis. Odont Revy 1958;9: 10–24.
20. Andreasen JO, Hjo¨rting-Hansen E. Intraalveolar root fractures. Radiographic and histology study of 50 cases. J Oral Surg 1967;25:414–26.
21. Andreasen JO, Hjo¨rting-Hansen E. Intraalveolar root fractures. Radiographic and histology study of 50 cases. J Oral Surg 1967;25:414–26.
22. Akyuz SN, Erdemir A. Restoration of tooth fractures using fiber post and fragment reattachment: Three case reports. Eur J Gen Dent 2012;1:94-8.
23. Canoglu H, Gungor HC, Cehreli ZC. Management of cervical root fracture using orthodontic extrusion and crown reattachment: a case report. Oral Surg Oral Med Oral Pathol Oral Radiol Endod. 2007 Sep;104(3):e46-9.
24. C. P .K. Wadhwani,1 .A single visit, multidisciplinary approach to the management of traumatic tooth crown fracture. British dental journal volume 188 no. 11 june 10 2000.
25. Graziella Silva Bittencourt1, Fl′avio Xavier de Almeida2 and Armelindo Roldi3. Intentional replantation with tooth rotation as indication for treatment of crown-root fractures. Brazilian Journal of Dental Traumatology (2009) 1(1): 2-6.
26. Andreasen JO, Hjørting-Hansen E. Intra-alveolar root fractures: radiographic and histologic study of 50 cases. J Oral Surg 1967;25:414–26.
27. Jens O. Andreasen. Pulp and periodontal tissue repair - regeneration or tissue metaplasia after dental trauma. A review .Dental Traumatology 2012; 28: 19–24.
28. Andreasen JO, Andreasen FM, Meja`re I, Cvek M. Healing of 400 intra-alveolar root fractures. 1. Effect of pre-injury and injury factors such as sex, age, stage of root development, fracture type, location of fracture and severity of dislocation. Dent Traumatol 2004; 20: 192–202.

29. Andreasen JO, Andreasen FM, Meja`re I, Cvek M. Healing of 400 intra-alveolar root fractures. 2. Effect of treatment factors such as treatment delay, repositioning, splinting type and period and antibiotics. Dent Traumatol 2004; 20: 203–211.
30. Jens Ove Andreasen1, Søren Steno Ahrensburg1, Georgios Tsilingaridis2. Tooth mobility changes subsequent to root fractures: a longitudinal clinical study of 44 permanent teeth. Dental Traumatology 2012; 28: 410–414.